

JOHN GUSTAF LINDBERG
1884-1973



The Discoverer of
Exfoliation Syndrome
1917

Helsinki 2017
Yliopistopaino

Survey of Eye Foundation
No 8, 2017

**JOHN GUSTAF
LINDBERG
(1884-1973)**

**The Discoverer of
Exfoliation Syndrome**

Ahti Tarkkanen
Tero Kivelä

FRÅN ÖGONSJUKHUSET I PETROGRAD
(ÖVERLÄKARE D:r E. BLESSIG)

KLINISKA UNDERSÖKNINGAR
ÖVER
DEPIGMENTERINGEN AV PUPILLARRANDEN
OCH GENOMLYSBARHETEN AV IRIS

VID FALL AV ÄLDERSSTARR SAMT I NORMALA
ÖGON HOS GAMLA PERSONER

AKADEMISK AVHANDLING

AV

J. G. LINDBERG
MED. LIC.

FRAMSTÄLLES MED TILLSTÅND AV MEDICINSKA FAKULTETEN
VID UNIVERSITETET I HELSINGFORS TILL OFFENTLIG GRANSK-
NING I HISTORISK-FILOLOGISKA AUDITORIET DEN 30 MAJ 1917
KL. 10 F. M.

PREFACE

Very few physicians have in the course of their research discovered an entirely new disease of worldwide distribution.

In Finland, Professor Erik Adolf von Willebrandt (1870-1949) described in 1926 the most common hereditary blood clotting disorder or hemophilia that like the mutated protein, von Willebrandt factor, now bears his name.

Åland Island Eye Disease, one type of an X-linked retinopathy, was discovered in 1964 by Dr. Henrik Forsius (b.1921), who later became Professor in Ophthalmology in Oulu, Finland, and Dr. Aldur W. Eriksson (1927-2015).

Even more rarely is a previously unknown disease published as a doctoral thesis. In 1973, Dr. Jouko Meretoja (1936-2002), also a Finnish ophthalmologist, defended his dissertation on a dominantly inherited systemic amyloidosis that had typical corneal findings. Officially known as Familial Amyloidosis, Finnish type and now also called systemic gelsolin amyloidosis, it is still widely known as the Meretoja Syndrome.

The booklet commemorates another Finnish ophthalmologist, John Gustaf Lindberg (1884-1973), who decided to write a thesis that would address a hypothesis floated in the early 1900's according to which progression of cataract was associated with decreasing pigmentation in the anterior segment of the eye. In the course of his research, Lindberg observed that some patients had distinct grayish intraocular flakes. He grew increasingly interested in this finding, enabling

him to serendipitously describe – unassociated as it was with his hypothesis – for the first time what we now know as exfoliation syndrome.

Lindberg drew conclusions that continue to hold true today but received almost no credit for his achievement during his lifetime. On the contrary, foreign colleagues to whom Lindberg disclosed his findings went on to publish them under their own name without mentioning him at all. Consequently, the work of Lindberg was soon forgotten.

Today, exfoliation syndrome is diagnosed daily in all populations across the world. It has emerged as one key risk factor for development and progression of open-angle and, in certain populations, closed-angle glaucoma, as well as for development of cataract. Moreover, the risk of adverse events during cataract extraction is significantly higher in patients with exfoliation syndrome.

Essentially all ophthalmologists encounter in their practice patients who have exfoliation syndrome. The importance of this syndrome has dramatically increased from the days of Lindberg.

We have the pleasure of summarizing here the life and the main original observations of John Lindberg for the delegates of the 7th World Glaucoma Congress on the occasion of the first centenary of the discovery of exfoliation that coincides with the centenary of the Republic of Finland.

Helsinki, May 30, 2017

Prof. Ahti Tarkkanen
Prof. Tero Kivelä

JOHN G. LINDBERG

Parents

The father of Dr. John Gustaf Lindberg, Gustaf Robert Lindberg (1844-1929), was an engineer who was born in Helsinki, Finland, at the time a Grand Duchy of Russia after having been a province of the Kingdom of Sweden until 1809 when the latter lost it in war.

Gustaf dropped out of school as a youngster, moved to the city of Kuopio, Eastern Finland, and enrolled as a stoker's assistant on a steamer to get practical experience in ship engines. He then sought formal education and graduated as a stoker and later as a machine operator, first class. On his spare time, Gustaf continued to study and graduated also as an engineer from the College of Advanced Technology located in Helsinki.

While working on steamers, Gustaf got to know St. Petersburg, the capital of Russia. He sought and got an appointment as a department manager in St. Petersburg Metal Works where he subsequently worked for many years. His task was to supervise the construction of boilers for steam engines and of metal bridges.

Meanwhile, Robert had married in Helsinki Anna Heloise Rautelin. During their St. Petersburg years, three boys were born to them. John Gustaf was the second one. St. Petersburg thus became his home town, a fact that later was to influence his research career and specialization in ophthalmology.

The family moved to Helsinki in the early 1890's after Gustaf had been offered a position as the Director of Technology in the recently founded company Kone ja Silta Oy (literally,

Machine & Bridge, today Wärtsilä Corporation, world leader in power sources for marine and energy markets with over 18,000 employees in over 70 countries).

After this appointment, Gustaf was elected to several trustee positions at both city and state level such as the presidency of the Employers' Organization for Industrial Companies. He also promoted development of vocational schools in Helsinki, was a board member of the Swedish speaking institute of technology in Finland, and an active member in the Joint Council of the Engineering Societies of Finland.

Medical Education

In 1903, at the age of 19, John Gustaf Lindberg matriculated from the Swedish speaking Real Lyceum in Helsinki. After preparatory studies for three years in botany, zoology, physics and chemistry in the University of Helsinki, John passed the medicophile examination that was a mandatory step before applying to the Faculty of Medicine.

John was successful and graduated in 1908 as Bachelor of Medicine, and six years later, in the spring of 1914, as Licentiate of Medicine. By that time he had acted for one year as an Assistant in Anatomy. However, he already had made up his mind to be an ophthalmologist.

From 1910 to 1913, John frequently assisted Dr. Johannes Silfvast (1867-1932) in the private eye hospital that the latter run in Helsinki, and spent the summer of 1912 as an intern in the city eye hospital affiliated with the University of Helsinki.

Marriage and Children

On April 1, 1913, John married Lilla Elisabeth Fazer, daughter of the Consul General Konrad Georg Fazer and Mrs. Jeanne Barrault. Lilla was also to help John as his combined research assistant, copy typist and assisting nurse in his private practice.

The first child Wanda Elisabeth was born in 1914, followed by Roger in 1915, and Konrad in 1918. Wanda became a nurse and married Kay-Erik Hartwall, the managing director of a family-owned mineral water company bearing the family name (today Danish-owned leader in the Finnish beverage industry). Roger became the managing director of Fazer Music Co. and held dozens of trustee positions related to trade and culture. He also became the President of the Board of Trustees of the Eye Foundation in Finland. Konrad became an engineer and the managing director of the Fazer Piano Factory.

Specialization

After graduating from the Medical School, John began specializing in ophthalmology. He spent the rest of 1914 working simultaneously as an intern at the Department of Surgery in the Maria Municipal Hospital and as a voluntary unpaid resident in the University Eye Hospital.

After mastering the basics, John enrolled as a voluntary resident in the Imperial Ophthalmic Hospital of St. Petersburg, the city of his birth. To sustain his family, John additionally worked as a general practitioner.

The Imperial Ophthalmic Hospital was one of the first that had been established in Europe, having been founded already in 1816. The very first eye hospital, Moorfields Eye Hospital in London, England, had been founded a decade earlier in 1805, followed by the Eye Clinic in Vienna, Austria, that was established in 1812 as the first university-associated eye hospital. The eye clinic in Berlin, Germany, was founded



Dr. Ernst Blessig, chair of the Imperial Ophthalmic Hospital in St. Petersburg and the supervisor of John G. Lindberg's doctoral thesis, portrait from the photographic collection of the University of Tartu, Estonia.

in 1817. The Helsinki University Eye Hospital was founded more than 50 years later, in 1871.

All professors in the Imperial Ophthalmic Hospital before the Russian Revolution of 1917 were of German origin.

During Lindberg's residency, the Chair of the eye hospital from 1900 was the scholar Dr. Ernst Friedrich Blessig (1859-1940) who was born in St. Petersburg. His father was Frederic Johann Blessig (1816-1887) who worked in the German Foreign Office in St. Petersburg and eventually led its First Bureau, while his uncle, Dr. Robert Blessig (1830-1878), also had been the Chair of the Imperial Ophthalmic Hospital in 1863-1878.

Ernst Blessig had studied in St. Petersburg and in German eye clinics. After the Revolution he moved to Tartu University, Estonia, where he became its Professor of Ophthalmology. His main research interests were glaucoma and eye injuries.

Doctoral Thesis

Lindberg started his research in 1915 while in the Imperial Ophthalmic Hospital. The aim of his research was to explore the theory that had been put forward two years earlier by Professor Karl Theodor Paul Polykarpus Axenfeld (1867-1930) in Freiburg, Germany, according to which pigmentation of the iris would decrease and the transparency of the iris increase simultaneously with the development of cataract.

Lindberg needed a slit lamp for his research. Today every ophthalmologist has a slit lamp in his office, but at the time this instrument was not yet commercially manufactured. In fact, the theory behind the slit lamp had only recently been presented by Professor Allvar Gullstrand (1862-1930), Uppsala, Sweden, in 1911. That year he also had received the Nobel Prize in Physiology or Medicine for studies on physical and physiological optics and the refraction of light in the eye.



Dr. Theodor Axenfeld, chair of the Eye Hospital in Freiburg and the proposer of the hypothesis that John G. Lindberg explored in his doctoral thesis.

Lindberg studied keenly the publication of Gullstrand. He got hold of an old Zeiss microscope, built from that his own slit lamp, and learned to use it, all by himself. Compared with his contemporaries, Lindberg was technically a decade ahead of his time.

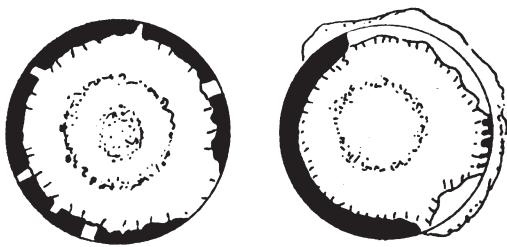
The material of Lindberg's thesis consisted of 202 patients older than 55 years, mostly from the Imperial Ophthalmic Hospital, even though some controls originated from the Kivelä City Hospital and Oulunkylä Old People's Home, both in Helsinki, Finland.

In the course of his work, Lindberg showed great talent in making detailed drawings of the anterior segment of the eye. No photographic technique for this purpose was yet available. Drawings and watercolors were used to record observations, which made many clinicians of that era comparable to skilled artists.

While examining his cataract patients and controls, Lindberg noted that many of them had small whitish flakes on the lens and pupillary border of their irides. He grew more and more interested in this novel observation. He found such white flakes in no less than one half of his glaucoma patients, although they were frequent in those with various types of cataract as well.

The association was strongest with the age of the patient. The flakes were most common among those who were the oldest. This was true even in his control patients. These observations still hold true.

Lindberg's doctoral thesis, which he wrote in Swedish and entitled "Kliniska undersökningar över depigmenteringen av pupillarranden och genomlysbarheten av iris vid fall av åldersstarr samt i normala ögon hos gamla personer" (in English: Clinical Investigations on Depigmentation of the Pupillary Border and the Translucency of the Iris in Cases of Senile Cataract and in Normal Eyes of Elderly Persons), was finished in early 1917. Lindberg defended it on May 30. Because the thesis was written in the Imperial Ophthalmic Hospital, his opponent was Prof. Väinö Grönholm (1868-



Original drawings by John G. Lindberg from his thesis. Case 89, age 70 years (left) with translated caption "A ring of greyish-blue dust on ant. capsule. Some of it also in the centre of the ring in both eyes. Cataracta intranuclearis incip. Slight central opacity of the lens." Case 110, age 73 years (right) with translated caption "On the ant. capsule a ring of greyish-blue dust. Cataracta subcaps. incip." The former was a case of bilateral, the latter a case of unilateral exfoliation syndrome.

1939) from the University of Helsinki, Finland. Grönholm's written evaluation of the thesis is dry and formal in style, despite the fact that he had a reputation of a vivid speaker. According to Grönholm, the thesis confirmed many earlier observations and also provided some new ones. The thesis fulfilled the academic requirements for the title of Doctor in Medical Sciences that is equivalent to Ph.D.

Lindberg's great discovery, the exfoliation syndrome, was not mentioned at all.

Independence of Finland

The increasing tumult of World War I (1914-1917) brought the Lindberg family to Helsinki in 1917 after the February Revolution (March in the Gregorian calendar used elsewhere in Europe) broke out in and around St. Petersburg following significant military setbacks for the Russian Army.

The February Revolution brought to power the Russian Provisional Government that was soon to be deposed by the Bolsheviks in the October (November) Revolution. Soon there-

after, on the 6th of December, Finland separated from Russia and declared independence.

John first practiced in the Eye Clinic of the Deaconess' Hospital in Vyborg, Eastern Finland, before he got an appointment as Resident in the University Eye Hospital in Helsinki by the end of 1917. Lindberg held this position until early 1920. He already had been licensed as a Specialist in Ophthalmology in Finland, so that it was not necessary for him to take an appointment as a resident. He considered such an appointment useful, however, so as to get a comprehensive training in every subspecialty of ophthalmology.

Stolen Idea

Although travelling abroad in the 1920's was expensive, slow and tedious, and no grants were available for this purpose, John Lindberg travelled in 1920 to the University of Freiburg, Germany, where he practiced research at the Department of Ophthalmology for one year. He also took part in the clinical work under the guidance of Prof. Theodor Axenfeld. John was to return to Freiburg in 1923 for three months to pursue experimental and clinical studies on naphthalene cataract, a topic current at the time.

A key event for European and also for many non-European ophthalmologists was the annual meeting of Deutsche Ophthalmologische Gesellschaft (German Ophthalmological Society) held in Heidelberg. Since 1920, John was a regular participant.

In Germany, Lindberg met Professor Alfred Vogt (1879-1943) from the University of Basel in Switzerland, and he gave him a copy of his thesis. Lindberg additionally briefed Vogt about his observations.

In 1923, Vogt published about exfoliation syndrome without mentioning Lindberg. Vogt proposed that exfoliation was a consequence of prior surgery for glaucoma, but this was soon shown to be an error. The same year, Vogt was nominated Professor of Ophthalmology to the

University of Zürich where he later conducted own valuable research in exfoliation syndrome. Vogt became widely known also in the United States, so much so that exfoliation syndrome was known there as Vogt's syndrome even as late as the 1950's.

In 1921, Lindberg attended for the first time the Nordic Congress of Ophthalmology held in Stockholm, Sweden. He regularly took part in this essential regional congress throughout his later career.

In Stockholm, John Lindberg met Dr. Birger Malling (1884-1989) from Tromsø, Norway, who also got to know about Lindberg's thesis. Like Vogt, Malling published about exfoliation syndrome in 1923 without any mention of Lindberg. Dr. Malling erred in concluding that exfoliation resulted from iridocyclitis. In 1939 he became Professor of Medicine in University of Oslo, Norway, but never cited Lindberg even in his later publications on this topic.

On the bright side, Lindberg had received a citation from another Norwegian colleague, Dr. Harald Gustav Antonio Gjessing (1882-1970) who mentioned his thesis in the bibliography of his own dissertation, published in 1920.

Lindberg took the opportunity to participate in international courses as well, e.g. in 1920 in Halle, Germany, and in 1926 in Basel. He also paid short visits to university eye hospitals in Scandinavia, Germany, Switzerland, and the United States. An international orientation like this was very rare among Finnish physicians of the nascent Republic in the 1920's.

Clinical Career

Having returned to Finland in 1923, the family moved for three years to Vyborg, where John Lindberg was appointed Chief Physician of the private eye hospital that had been envisioned by Prof. Gustaf Julius Strömborg (1830-1899) so that when the hospital was opened in 1906, it was named after Strömborg. He was the only ophthalmologist not only in Vyborg but also in



Strömborg's Eye Hospital in Vyborg where John G. Lindberg was the Chief Physician from 1923 to 1928, image from the collection of the Päijät-Häme Central Hospital.


the entire Karelian Isthmus, and the very first specialist who had any research background.

The inhabitants of Karelia were plagued by trachoma, and eye injuries were not infrequent. No antibiotics or sulfonamides were available, and trachoma was mostly managed by everting the eyelids and rupturing the granules, as well as by using compresses, topical silver nitrate, and topical zinc sulfate. Managing trachoma was painstaking and time consuming. Lindberg kept detailed statistics of his treatments. These show that his days were exceptionally busy.

In 1929, John Lindberg got an appointment in Helsinki as Clinical Instructor (comparable to Assistant Professor) in the University Eye Hospital for four years, and he also founded a private practice that he ran for almost 40 years. Moreover, he was the acting ophthalmologist in the Central Military Hospital.

The City of Helsinki maintained from the 19th Century onward an eye casualty of its own that was attached to the Department of Surgery, Maria Municipal Hospital. In 1935, Lindberg got an appointment as its Chief Physician.

When the State of Finland in 1937 failed to fulfill its promise to develop a new building for the University Eye Hospital, the City founded its own Department of Ophthalmology in the Kivelä Municipal Hospital. Lindberg was now chosen to be its first Chief Physician, a position that he held for 14 years until he retired in 1951 at the age of 65 years. However, he continued his private practice for more than a decade.



The newly built Kivelä Municipal Hospital in Helsinki where John G. Lindberg was the Chief Physician of the Department of Ophthalmology for 14 years, image from the collection of the Helsinki City Museum.

Lindberg was a respected physician beloved by his staff, a clever clinician, an able surgeon, and a good teacher. He was a frequent speaker in both domestic and international congresses. Many ophthalmologists got part of their clinical training under his supervision in the Kivelä Hospital. He also functioned as the President of Finska Läkaresällskapet (the Swedish speaking Medical Society in Finland), was two times the President of the Ophthalmological Society of Finland, and a member in committees of the Finnish Medical Association.

Legacy

In 1936, the Norwegian ophthalmologist Dr. Eivind Hørven (1896-1985) from the University of Oslo cited Lindberg's thesis in a paper that he presented in the Nordic Congress of Ophthalmology and published the next year in the British Journal of Ophthalmology.

The published discussion that followed the presentation includes thanks from Lindberg to Hørven for resurrecting his thesis that had been forgotten for almost 20 years, and for crediting him as the discoverer of exfoliation syndrome.

Indeed, knowledge of exfoliation syndrome remained very limited in the 1920's and 1930's. The most significant studies at that time were published, in addition to Prof. Alfred Vogt and Dr. Eivind Hørven, by Dr. Archimede Busacca (1893-1971) – who was the first to study the

histopathology of exfoliation syndrome – in Italy in 1927, Dr. Alexis Trantas (1867-1961) in Greece and Vogt's student Dr. Karl Rehesteiner (1886-1956) in Switzerland in 1929 and Dr. Amin A. El-Maghraby in Egypt in 1937.

Important histopathologic work was later published by Dr. Georgiana Dvorak Theobald (1884-1971) in the United States in 1954 and Dr. Olav Aga Sunde (1911-1987) in Norway in 1956. The second Finnish thesis on exfoliation syndrome was initiated in 1959 when Prof. Ahti Tarkkanen (b. 1930) was given this topic and made award of Lindberg's thesis. His thesis entitled "Pseudoexfoliation of the Lens Capsule. A Clinical Study of 418 Patients with Special Reference to Glaucoma, Cataract, and Changes of the Vitreous" was published in 1962.

In 1989, Prof. Tarkkanen and Prof. Henrik Forsius (b. 1921) from Oulu, Finland, published an English translation of Lindberg's thesis as a Supplement to *Acta Ophthalmologica*, so as to make it widely available to researchers.

Further Finnish dissertations on exfoliation syndrome have been published by Dr. Jaana Hietanen, Dr. Marita Uusitalo and Dr. Päivi Puska, all in 1995, Dr. Mika Harju in 2001, Dr. Pia Ehrnrooth in 2005, and Dr. Susanna Lemmelä in 2009.

The Lindberg Society

The 1st International Workshop on Exfoliation Syndrome was held in 1987 in Helsinki, Finland, followed by the 2nd in 1992 in Genoa, Italy, and the 3rd in 1995 in Erlangen, Germany. These were followed by informal Think Tanks organized in New York by Prof. Robert Ritch from 1999 onward.

In 1998, the time was ripe for founding an international society for investigators sharing an interest in exfoliation syndrome. The society adopted the name "The Lindberg Society", and has since met regularly across the world, like at the present 7th World Glaucoma Congress.

EPILOGUE

The earlier terms for exfoliation syndrome and exfoliation glaucoma, “senile exfoliation” and “glaucoma capsulare” were proposed by Prof. Alfred Vogt.

Dr. Georgiana Dvorak Theobald introduced the term “pseudoexfoliation” and Dr. Olav Aga Sunde proposed “exfoliation syndrome”. Prof. Gottfried O. H. Naumann (b. 1935) Erlangen, Germany, merged these terms into “pseudoexfoliation syndrome”. Of alternative proposals, “epitheliocapsular fibrillopathy”, put forward by Prof. Torstein Inge Bertelsen (1923-2008) from Bergen, Norway, never became popular.

Despite some effort, a worldwide consensus about the preferred term has not been reached. The first effort was taken during the 2nd International Symposium on Exfoliation that was held in Genoa, Italy, in 1992. Luckily, variable terminology has never introduced any serious misunderstandings.

During the last five years, the most common term has *de facto* been “exfoliation syndrome” that features in 411 papers listed in PubMed, as opposed to 233 papers that use the term “pseudoexfoliation syndrome”, and 87 papers that use just “pseudoexfoliation” without “syndrome”.

In contrast, “pseudoexfoliation glaucoma” predominates in publications that deal with the secondary open-angle glaucoma associated with exfoliation syndrome, being used in 134 papers, although the terms “exfoliation glaucoma” in 68 papers, “pseudoexfoliative glaucoma” in 54 papers, and “exfoliative glaucoma” in 35 papers also are in use. However, “capsular glaucoma” has fallen into oblivion, being used in only one paper during the most recent five year period.

The authors prefer “exfoliation syndrome”, which has become the most common term, and “exfoliation glaucoma” as the most natural pair for the parent term.

BIBLIOGRAPHY

- Axenfeld T (1911): Über besondere Formen von Irisatrophie, besonders die hyaline Degeneration des Pupillarsaumes und die pupillare Pigmentatrophie des Iris hinterblattes. *Bericht Ophthalmol Gesellschaft Heidelberg* 37: 255–235.
- Axenfeld T (1913): Weitere Erfahrungen über Pigmentdegeneration des retinalen Pupillarsaumes. *Bericht Ophthalmol Gesellschaft Heidelberg* 39:276–285.
- Bertelsen T, Drablos PA, Flood PR (1964): The so-called senile exfoliation (pseudoexfoliation) of the anterior lens capsule, a product of the lens epithelium. Fibrilloglycopathia epitheliocapsularis. *Acta Ophthalmol (Copenh)* 42:1096–1113.
- Busacca A (1927): Struktur und Bedeutung der Häutchen-niederschläge in der Vorderen und hinteren Augenkammer. *Arch f Ophthalmol* 119:135–176.
- Dvorak Theobald G (1954): Pseudo-exfoliation of the lens capsule. Relation to “true” exfoliation of the lens capsule as reported in the literature and role in the production of glaucoma capsulocuticularis. *Am J Ophthalmol* 37:1–12.
- Ehrnrooth P (2005): *Long-term Outcome of Trabeculectomy in Primary Open-angle Glaucoma and Exfoliation Glaucoma*. Thesis. Helsinki.
- Gjessing H (1920): *Kliniske Linstudier*. Thesis. Drammen.
- Gullstrand A (1911): *Einführung in die Methoden der Dioptrik des Auges*. S. Hirzel, Leipzig.
- Harju M (2001): *Exfoliation Glaucoma: Studies on Intraocular Pressure, Optic Nerve Head Morphometry, and Ocular Blood Flow*. Thesis. Helsinki.
- Hietanen J (1995): *Histopathological and Lectin Histochemical Study of Exfoliation Syndrome*. Thesis. Helsinki.
- Hørven E (1936): Wie häufig kommt Abschlüpfung des Linsenvorderkapsel (Vogt) beim Glaukoma simplex vor? *Acta Ophthalmol (Copenh)* 14:231–245.
- Hørven E (1937): Exfoliation of the superficial layer of the lens capsule (Vogt) and its relation to glaucoma simplex. *Br J Ophthalmol* 21:625-37.
- Lemmelä S (2009): *Molecular Genetics of Primary Open Angle Glaucoma and Exfoliation Syndrome*. Thesis. Helsinki.
- Lindberg JG (1917): *Kliniska Undersökningar över Depigmentering av Pupillarranden och Genomlysbarheten av Iris vid Fall av Åldersstarr samt i Normala Ögon hos Gamla Personer*. Thesis. Helsinki.
- Lindberg JG (1917): *Clinical investigations on depigmentation of the pupillary border and translucency of the iris in cases of senile cataract and in normal eyes in elderly persons*. *Acta Ophthalmol (Copenh) Suppl.* 190: 1–96. [English translation, 1989]
- Maghraby A (1937): Glaucoma capsularis. *Bull Ophthalmol Soc Egypt* 30:42–50.
- Malling B (1923): Untersuchungen über das Verhältnis zwischen Iridocyclitis und Glaukom. *Acta Ophthalmol (Copenh)* 1:97–130.
- Malling B (1923): Untersuchungen über das Verhältnis zwischen Iridocyclitis und Glaukom. II Klinische Versuche. *Acta Ophthalmol (Copenh)* 1:215–231.
- Malling B (1938): Einige Untersuchungen über sogenannte Kapselglaukom. *Acta Ophthalmol (Copenh)* 16: 43–69.
- Puska P (1995): *Exfoliation syndrome. A Risk Factor for Glaucoma and Lens Opacification*. Thesis. Helsinki.
- Rehsteiner K (1929). Beitrag zur Kenntnis des Linsenkapselhäutchenglaukom. *Klin Monatsbl Augenheilkd* 82: 21–36.
- Ritch R & Schlötzer-Schrehardt U (2001): Exfoliation (pseudoexfoliation) syndrome: toward a new understanding. Proceedings of the First International Think Tank. *Acta Ophthalmol Scand* 79:213–217.
- Sunde OA (1956): On the so-called senile exfoliation of the anterior lens capsule. A clinical and anatomical study. *Acta Ophthalmol (Copenh) Suppl.* 45:1–85.
- Tarkkanen A (1962): Pseudoexfoliation of the lens capsule. A clinical study of 418 patients with special reference to glaucoma, cataract and changes of the vitreous. *Acta Ophthalmol (Copenh) Suppl.* 71:1–98.

Tarkkanen A & Forsius H. (1988): Exfoliation syndrome. *Acta Ophthalmol (Copenh) Suppl.* 184:1–150.

Tarkkanen A & Kivelä T (2002): John G. Lindberg and the discovery of exfoliation syndrome. *Acta Ophthalmol Scand* 80:151–154.

Trantas A (1929): Lesions seniles de la capsule anterieure du cristallin et du bord pupillaire. *Arch Ophthalmol* 46:482–491.

Uusitalo M (1995): *The HNK-1 Carbohydrate Epitope in the Anterior Segment of the Eye: The Inner Connective Tissue Layer of the Human Body as a Distinct Element.* Thesis. Helsinki.

Vogt A (1923): Flaumige weisse Pupillarsaum Auflagerungen nach Trepanation. *Arch f Augenheilkd* 79: 389–394.

Vogt A (1923): Weitere Ergebnisse der Spaltenlampenmikroskopie des Vorderen Bulbusabschnittes, VIII Abschnitt. Über die pathologisch veränderte Iris. *Arch f Ophthalmol* 111:91–127.

Vogt A (1925): Ein neues Spaltlampenbild des Pupillargebietes: Heilblauer Pupillarsaumfilz mit Häutchenbildung auf der Linsenvorderkapsel. *Klin Monatsbl Augenheilkd* 75:1–12.

Vogt A (1926): Ein neues Spaltlampenbild: Abschilferung des Linsenvorderkapsel als wahrscheinliche Ursache von senilem chronischen Glaukom. *Schweiz Med Wochenschr* 56:413–423.

